

Case of the Month—September 2005

## FDG-PET for Staging Lung Cancer

### History

A 75-year-old female presented with newly diagnosed non-small-cell lung cancer. A recent CT scan showed a mass in the right lung and mediastinal adenopathy. PET was ordered for further staging for this patient.

### Findings

The FDG-PET scan revealed a large focus of intense FDG uptake in the right upper lobe of the lung, which is consistent with the patient's known cancer. Foci of abnormal uptake in the mediastinum are also present. In addition, there is a focus of intense FDG uptake in the right anterior chest wall (Figure 1B). There was no obvious lesion seen on CT initially. However, when compared side by side, the PET and CT studies reveal a subtle bone lesion that involves the right anterior seventh rib (Figure 1A and Figure 2).

### How Did PET Help?

The PET exam identified additional bone metastasis that was not obvious on clinical exam or CT study. The PET finding upgraded the patient's clinical staging from IIIA to IV.

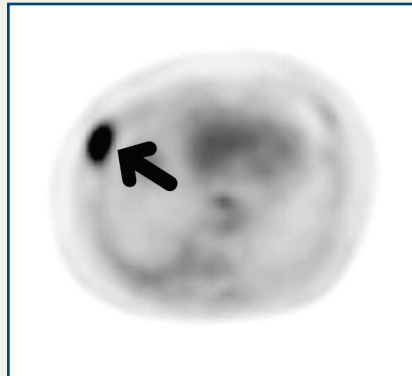


Figure 1A—PET scan

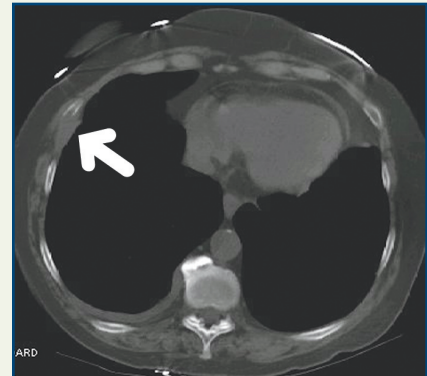


Figure 2—CT scan

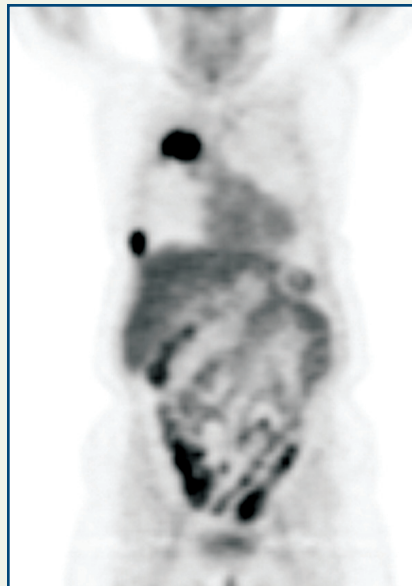


Figure 1B—PET scan

### Discussion

Many studies have demonstrated that FDG-PET is superior to conventional imaging such as CT for staging lung cancer patients. In a patient with lung cancer, PET is useful both to detect extrathoracic metastasis and for mediastinal lymph node staging. Unexpected extrathoracic metastases were detected by PET in 15% of patients in one study<sup>1</sup>. The negative and positive predictive values were 71 and 83% for mediastinal lymph node staging<sup>1</sup>.

(1) *Lung Cancer*: 2004 May; 44(2): 175-81

Copyright 2005 New England PET Imaging System

[www.nepetimaging.com](http://www.nepetimaging.com)

NEPET at Holy Family Hospital  
 70 East Street  
 Methuen, MA 01844  
 (978) 689-4738

NEPET of Greater Lowell  
 Lowell General Hospital Cancer Center  
 295 Varnum Avenue  
 Lowell, MA 01854  
 (978) 458-9872

NEPET at Elliot Hospital  
 One Elliot Way  
 Manchester, NH 03103  
 (603) 663-2370

Massachusetts Mobile PET, P.C.  
 at Anna Jaques Hospital  
 25 Highland Avenue  
 Newburyport, MA 01950  
 (888) 560-4738

Massachusetts Mobile PET, P.C.  
 at Merrimack Valley Hospital  
 140 Lincoln Avenue  
 Haverhill, MA 01830  
 (888) 560-4738