

^{18}F NaF PET bone imaging vs. planar $^{99\text{m}}\text{Tc}$ MDP in a patient with breast cancer

Clinical History

A patient with a history of breast cancer presented with increasing back pain two weeks after her fall. The patient was referred for a whole body planar bone scan.

Imaging Findings

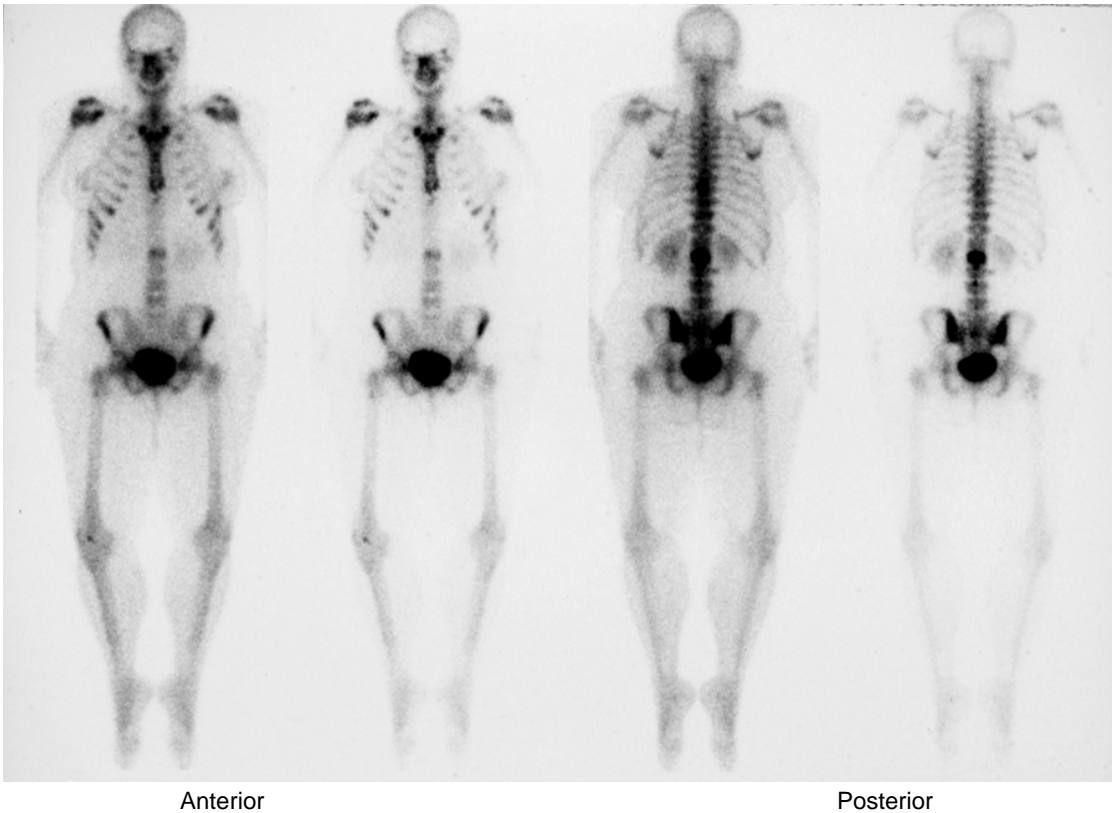


Fig. 1

Bone Scan Findings

A planar whole body bone scan was performed with 30 mCi $^{99\text{m}}\text{Tc}$ MDP, 3 hour delay, and spot views of the spine and pelvis. The bone scan revealed abnormal activity in the L2 vertebral body that could have been metastatic disease or a post-traumatic fracture. There was minimal focal activity in the left 7th rib, which was also suspicious for metastatic disease versus trauma (Fig. 1).

An MRI of the lumbar spine was suspicious for possible bone marrow metastases, and an FDG PET scan was ordered for restaging prior to treatment planning. (MRI images not shown).

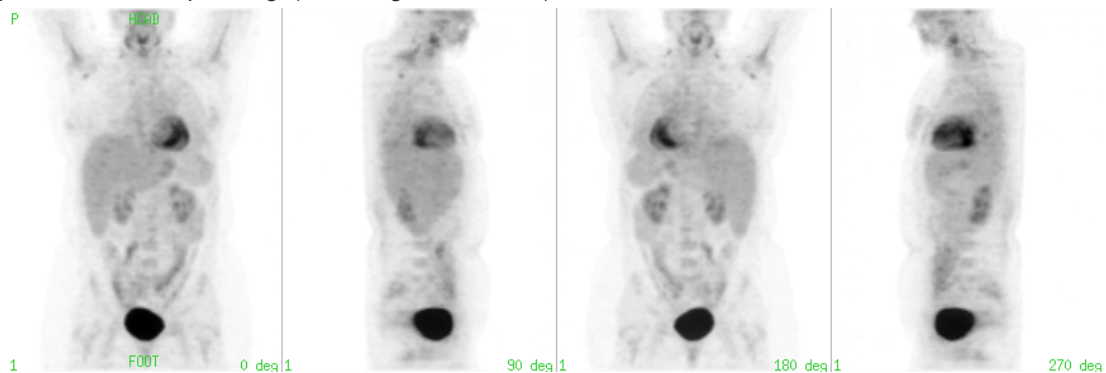


Fig. 2

FDG PET Scan Findings

A PET scan was performed after injection of 10 mCi of FDG. No abnormalities were seen. Since FDG PET can be negative in sclerotic or osteoblastic bone lesions, further evaluation with ^{18}F Na was recommended. An ^{18}F Na PET scan was ordered to confirm the presence and extent of bone marrow metastasis prior to treatment planning.

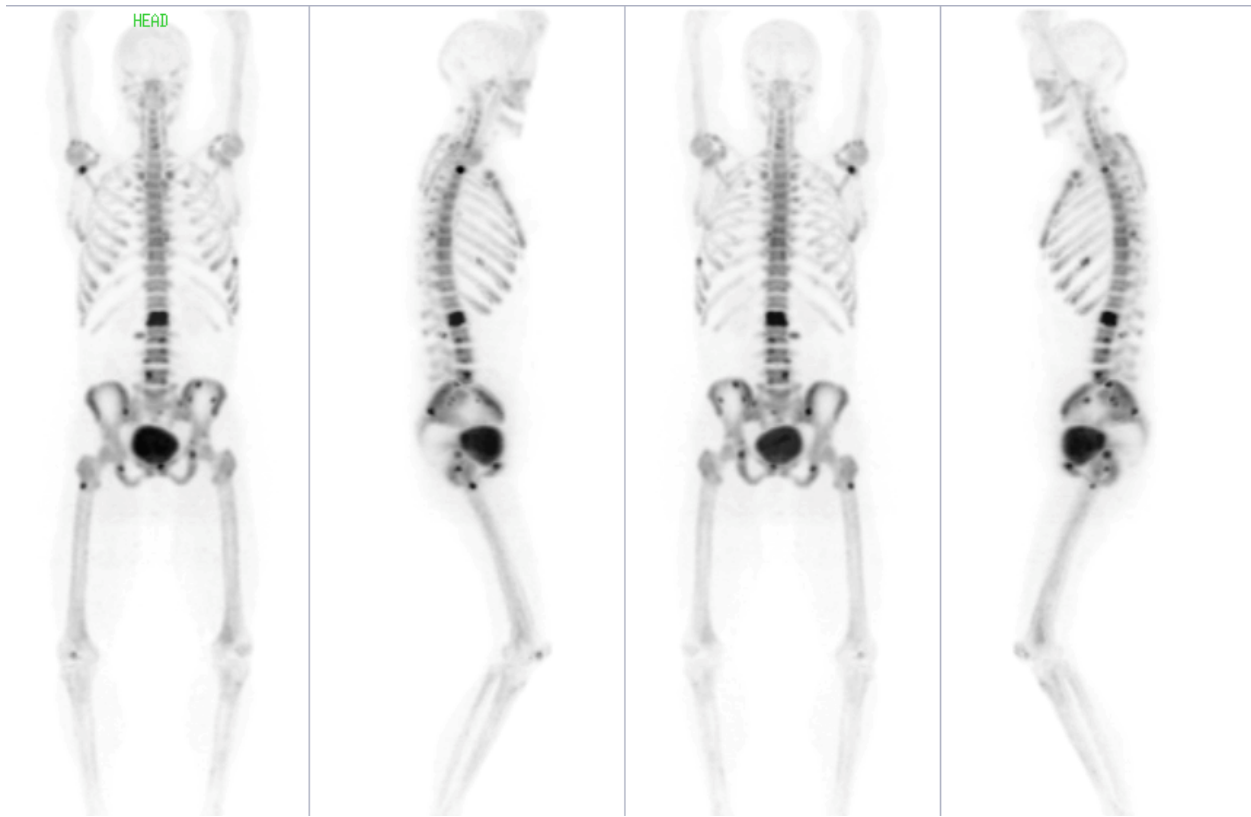
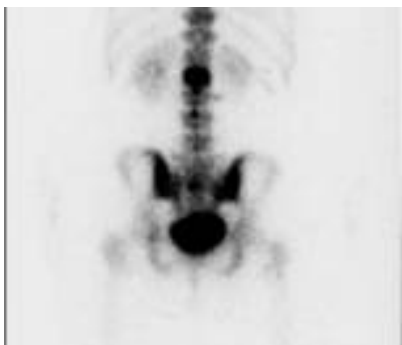
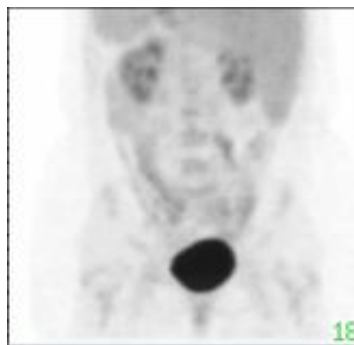
Fig. 3

¹⁸F NaF PET Scan Findings

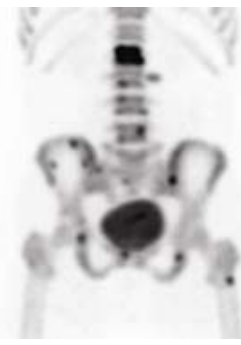The ¹⁸F NaF PET scan revealed abnormal uptake consistent with metastatic disease in the vertebral body of the L2 vertebra. Additional foci were noted in vertebral bodies L3, L5, the superior end plate of L4, and the right transverse process of L3; all consistent with metastatic bone disease that was not visualized in the FDG PET scan. Innumerable lesions were identified in the pelvis that were appreciated only in retrospect on a prior CT scan. Focal uptake in the left 7th rib and right glenoid were consistent with metastatic disease. Additional focus of activity was seen in the proximal metaphysis of the right femur that was faintly visualized, if at all, on the bone scan.



30 mCi ^{99m}Tc MDP



10 mCi ¹⁸F FDG



10 mCi ¹⁸F NaF

Treatment

The patient received appropriate systemic chemotherapy after accurate identification of the presence and the extent of bone disease with ¹⁸F NaF PET bone imaging.

Discussion

The most prevalent cancers in the United States are commonly associated with metastatic bone disease and the exclusion of metastatic bone disease is required prior to the initiation of potentially curative therapy.

The standard diagnostic method since the 1970's is planar or SPECT scintigraphy using ^{99m}Tc labeled polyphosphonates. Studies by Schirmeister et al. demonstrated that planar bone scintigraphy was 80-90% sensitive in the detection of peripheral skeletal metastases, but as low as 20-40% sensitive in the detection of vertebral metastases.¹

Evaluation of metastatic bone disease is possible using FDG PET. FDG accumulates in all cells relative to increased glucose metabolism. Soft tissue as well as bony metastatic sites can demonstrate FDG uptake, making precise anatomic localization

of lesions difficult.

^{18}F NaF is preferentially deposited at sites of high bone turnover and remodeling, and bone metastases are seen indirectly because uptake depends on skeletal reaction to the tumor. Tracer kinetics depend on both regional blood flow and osteoblastic activity^{2,3} with bone uptake two times higher and blood clearance is faster than $^{99\text{m}}\text{Tc}$ labeled polyphosphonates⁴, resulting in superior bone to background ratio.

^{18}F Na PET has the ability to offer an improved whole body tomographic technique for assessing the presence and extent of bone metastases and has the potential to influence referring physician adoption by introducing the diagnostic utility of molecular imaging for the common clinical problem of evaluating metastatic bone disease.

Data courtesy David Halsey, MD and Gustavo Mercier, MD, Seattle Nuclear Medicine, Seattle, WA

References:

1. Schirrmester, H et al. Sensitivity in detecting osseous lesions depends on anatomic localization: planar bone scintigraphy versus ^{18}F PET. J Nucl Med 1999; 40: 1623-1629
2. Harmer, C L et al. The value of fluorine-18 for scanning bone tumours. Clin Radiol 1969; 20: 204-212
3. Holsti, L R, Patomaki, L K. ^{18}F scanning of primary and metastatic bone tumours. Ann Med Intern Fenn 1967; 56: 131-135
4. Schirrmester, H et al. Early detection and accurate description of extent of metastatic bone disease in breast cancer with fluoride ion and positron emission tomography. J Clin Oncol. 1999; 17(8): 2381-2389

* Any of the protocols presented herein are for informational purposes and are not meant to substitute for clinician judgment in how best to use any medical devices. It is the clinician that makes all diagnostic determinations based upon education, learning and experience.